

# CASE STUDY

## Resolution of Otitis Media in a Nine Month Old Undergoing Chiropractic Care: A Case Study and Selective Review of the Literature

Pamela Stone-McCoy B.S., D.C., CACCP<sup>1</sup> Alissa Boutilier B.A., D.C.<sup>2</sup> Paige Black D.C.<sup>3</sup>

### Abstract

**Objective:** To describe the chiropractic care of a pediatric patient with otitis media and vertebral subluxations.

**Clinical Features:** A nine-month-old boy, with a history of recurring ear infections, was presented by his mother for chiropractic evaluation and possible care. The mother reported that antibiotic therapy was unsuccessful. Myringotomy and insertion of tympanostomy ventilating tubes were recommended by the patient's ear nose and throat doctor (ENT).

**Intervention and Outcomes:** Care was initiated during an episode of otitis media. The patient was most commonly cared for using the Webster toggle headpiece and the Activator instrument. Cranial adjusting and sinus work was also utilized when necessary. Paraspinal thermal scans were performed to assess asymmetries due to vertebral subluxations. Both ears were reported clear within a week of initiating chiropractic adjustments and no ear infections have been reported since.

**Conclusions:** Chiropractic care in this case resulted in a reduction of the symptoms associated with otitis media and eliminated the need for myringotomy, tympanostomy tubes and antibiotics.

**Key Indexing Terms:** *Otitis media, chiropractic, subluxation, pediatrics, adjustment, spinal manipulation, thermography, Activator; ear infections, myringotomy, tympanostomy tubes*

### Introduction

The most frequent reason for physician visits for children in the United States, under the age of fifteen is otitis media.<sup>1</sup> Acute otitis media is the most common infection for which antibacterial agents are prescribed for children in the United States.<sup>2</sup> In 1990 there were more than 20 million prescriptions

for otitis media-related antibacterials prescribed and 25 million visits made to office-based physicians in the United States for this condition.<sup>2</sup> Approximately 10% of infants by 3 months of age will have had an episode of acute otitis media. 50% of children by 3 years of age will have had more than three episodes of acute otitis media.<sup>3</sup> The annual costs associated with the management of pediatric otitis media has been estimated at \$5.3 billion.<sup>4</sup>

1. Private Practice of Chiropractic, Kennesaw, GA
2. Private Practice of Chiropractic, Manchester, NH
3. Private Practice of Chiropractic, Lilburn, GA

Acute otitis media results in inflammation of the middle ear and is caused by bacteria in 70% of cases. Characteristic findings in bacterial cases of acute otitis media involve redness and bulging of the tympanic membrane.<sup>5</sup> Viruses elicit acute otitis media in about 30% of cases and in prolonged courses of acute otitis media, both bacterial and viral infections have been observed.<sup>5</sup> Otitis media with effusion is effusion of the middle ear without symptoms of acute inflammation such as pain and fever. Frequently the tympanic membrane in this case is amber or opaque in color.

The most common cause of childhood hearing loss is chronic otitis media. It can result in developmental impairment affecting linguistic, behavioral, motor and social skills.<sup>6, 7</sup> *Haemophilus influenzae*, *Streptococcus pneumoniae* and *Moraxella catarrhalis* are the most common pathogens found responsible for bacterial infections in otitis media with effusion.<sup>2,5,6</sup>

Otitis media is not a primary disease but instead a complication of other conditions; examples including coryza and sinusitis.<sup>8</sup> There is still much discussion and debate pertaining to the understanding and cause of middle ear infections in children.

It seems that the pathogenesis of otitis media is best explained by Eustachian tube dysfunction combined with a viral and/or bacterial infection, as well as various predisposing factors. In the early years of life the Eustachian tubes are oriented horizontally, thereby reducing the gravitational effect of middle ear drainage. This anatomical feature may contribute to residual fluid seen behind the tympanic membrane after an episode of otitis media.<sup>9</sup> A normally functioning Eustachian tube provides the following effects: (1) protection of the middle ear (2) drainage of fluid from the middle ear back into the nasopharynx, and (3) regulation of pressure in the middle ear to equilibrate with the outside environment.<sup>9</sup>

According to the American Academy of Pediatrics and the American Academy of Family Physicians clinical practice guidelines (of 2004) for the management of acute otitis media, an "observation option" for acute otitis media is recommended.<sup>2</sup> The "observation option" (according to the AAP and AAFP) refers to "deferring antibiotic treatment for 48-72 hours and limiting management to symptomatic relief."<sup>2</sup> Criteria for the "observation option" according to these guidelines include: "otherwise healthy children six months to two years of age with nonsevere illness at presentation and an uncertain diagnosis and to children two years of age and older without severe symptoms at presentation or with an uncertain diagnosis."<sup>2</sup> The increased bacterial resistance in respiratory infections has resulted in this approach.

Rosenfeld and Kay reported that by 24 hours 61% of children had decreased symptoms whether they received a placebo or an antibacterial. By seven days 75% of children had a resolution of symptoms.<sup>2</sup> A follow up survey conducted by the AAP and AAFP showed that only about 15% of responding physicians used the observation option.<sup>10</sup>

Prescribed treatment is typically a course of antibiotics. 80/90 mg/kg per day of amoxicillin is the recommended first line therapy for antibiotic management of acute otitis media

resulting from *streptococcus pneumoniae*.<sup>2</sup> When  $\beta$ -lactamase positive *Haemophilus influenzae* and *Moraxella catarrhalis* is present then treatment should be initiated with high-dose amoxicillin-clavulanate (90 mg/kg per day of amoxicillin with 6.4 mg/kg per day of clavulanate in 2 divided doses.)<sup>2</sup> There is much variation regarding the antibiotics prescribed and the length of treatment for acute otitis media.<sup>10</sup> Commonly, myringotomy and tympanostomy tubes are recommended for management of chronic otitis media with effusion. Hall and Lawrence reported that half a million tympanostomies were performed in 1996 alone.<sup>11</sup>

Problems with antibiotic use include: allergic reactions and cross-reactions, GI upset, destruction of the gut's natural flora, cost, and the increased resistance of pathogens to antibiotics thereby necessitating stronger antibiotics.

It has been estimated that 27-32% of tympanostomies performed might be unnecessary.<sup>12</sup> Taking into account the risks associated with myringotomy and tube insertion make this statistic troubling. Risks include: cholesteatoma, persistent tympanic membrane perforation, tympanosclerosis as well as the additional risks associated with anesthesia or sedation necessary for the procedure.<sup>1,5,7,8</sup>

This case study will discuss the chiropractic evaluation and management of a nine month old boy with otitis media and vertebral subluxations.

## Case Report

### Patient History

The patient is a 9 month old male Caucasian whose mother brought him into the chiropractic clinic at nine months of age complaining of recurring ear infections with the possibility of having tube placement in the ears.

At the time of birth the patient weighed 6 lbs. 11oz. and was 19 inches in length. A caesarian section was performed due to the small size of the mother's pelvis. The patient was not in a vertex position at the time of birth; the head was in some other position besides down. The mother was not on any medications during pregnancy and she did not smoke or consume alcohol. The patient was breastfed for the first six months and was on formula for 3 months; no cow's milk has been given to the child. He began solid food at the age of six months. No food or juice allergies or intolerances have been reported. The patient was reported having 10-11 hours of good quality sleep per night.

He has had no head first falls, no involvement in high impact sports, no emergencies, traumas, prior surgery or known childhood diseases. The mother states that the ear infections started after four months of vaccinations; he was four months old at the time. The child was administered antibiotics and was afflicted with ear infections about every three weeks. Claritin was prescribed to the patient for allergy control; he took a ½ teaspoon daily. The mother started daycare with him at five months of age, and stopped daycare at eight months of age. His mother, who was referred by a friend who had a child with similar symptoms and showed favorable results with chiropractic care, brought the child into the chiropractic

clinic.

### *Chiropractic Examination*

At nine months of age the patient weighed 18 lbs. and was 28 inches in length. The initial chiropractic examination showed the patient had ear infections and slight torticollis. Upper cervical, thoracic and sacral subluxations were identified.

A paraspinial thermal scan was performed using the Insight Millennium Subluxation Station™. The thermal scan assesses the sympathetic nervous system by measuring paraspinial skin temperature differentials. The right side of the body compared to the left side of the body at the same spinal level should have symmetrical readings.<sup>13</sup> Any differences are noted and compared to a normative database. Temperature differences one to two standard deviations above normal indicates mild asymmetry, two to three standard deviations above normal indicates moderate asymmetry, and three to four standard deviations above normal indicates severe asymmetry.

The patient's thermal scan showed the following results: mild asymmetry was found at the level of the third lumbar (L3) vertebrae on the right. Moderate asymmetry was found at the level of the first sacral (S1) vertebrae on the right. Severe asymmetry was found at the first cervical (C1) vertebrae on the right, the second cervical (C2) vertebrae on the right, and the eleventh thoracic (T11) vertebrae on the right. After review of the examination findings, the patient was accepted as a chiropractic case (See Figure 1).

### *Intervention*

The patient started his care plan the following day; three days per week with an assessment every visit. A subluxation with hypomobility was found and adjusted at the second cervical (C2) level of the spine on the left-hand side using the Infant Toggle Headpiece developed by Larry L. Webster, DC. The patient also received light pressure on the frontal zone to stimulate release of sinus pressure. The patient did not sleep well that night and returned the next day to the clinic for a follow-up.

A subluxation was found again at the second cervical (C2) level on the left, and again was adjusted using the toggle headpiece. Light pressure was applied to the frontal zone again to help alleviate sinus pressure. A special instruction session followed the adjustment for proper nutritional counseling. The patient was recommended to begin taking Omega 3's and Juice Plus. Juice Plus is a whole food based product that provides necessary nutrients from vegetables, fruits, and grains.

Two days later, the patient was subjectively doing better and "slept great". Multiple subluxations with spasm, hypomobility and end point tenderness were found and adjusted at the following levels: the first cervical (C1) vertebrae on the left using the toggle headpiece, the sacrum using the Activator instrument, and the cranium. The Activator instrument gives a consistent low-force, high-speed adjustment to the spine. The cranial adjustment is a non-force indirect method developed by Carol J. Phillips, DC. The main goals of the technique is first to restore cerebrospinal fluid flow and second, to restore

balance to the reciprocal membranous tension within the cranial system, which will improve function of the nervous system.<sup>14</sup>

The following week the patient came into the clinic and the mother reported that the child was pulling at the right ear and was not sleeping well. Upon examination, both ears were clear, with some wax but no fluid. Multiple subluxations with spasm, hypomobility and end point tenderness were found and adjusted at the following spinal levels: the first cervical (C1) vertebrae on the right and the first thoracic (T1) vertebrae. C1 was adjusted using the toggle headpiece and T1 was adjusted using the Activator instrument. The patient was seen twice more during that week with adjustments made at C1, T1, and sacrum. Cranial and sinus work was administered as well.

During the third week of care, the patient came into the clinic three times and was subjectively doing well and by the end of the week was not pulling on his ears. Adjustments were made at the following levels: C1, T1, and sacrum. The care plan was reduced to two times per week starting the fourth week of care. Both ears were clear and the patient was assessed as showing improvement. Adjustments were made at the C1, L5 and sacral levels of the spine.

A re-examination was performed in the fifth week of care. He had not had any ear infections since the start of care. The mother reported his naps were longer and he was getting better quality sleep. A thermal scan was performed and showed favorable results (See Figure 2). The C1 vertebra was adjusted on the left using the Activator instrument.

### *Outcome*

The patient was in the clinic once during the sixth week of care and subluxations with spasm, hypomobility and end point tenderness were found and adjusted at the following levels: C1 on the left, T1 and sacrum. During the seventh week of care the patient also visited his ENT. His ears were reported as clear with no need for tubes. Multiple subluxations were found and adjusted at the following levels: C1 on the left, T1 and sacrum. The patient had responded to treatment, and his condition was well controlled. He was no longer on Claritin and the care plan was reduced to one time per week during the following month of care. The patient caught a virus during this time but no ear infections ensued. The mother started the patient in daycare again. Follow-up thermal scans reveal a persistent pattern of dysfunction in the upper cervical spine that continues to be monitored (See Figure 4).

### **Discussion**

#### *Background*

A healthy functioning Eustachian tube performs the following actions: first, it protects the middle ear from infected nasopharyngeal fluid, bacteria and viruses. Second, it regulates the pressure in the middle ear to equalize with the external environment. Third, it drains the fluid from the middle ear back to the nasopharynx.<sup>9</sup> The tensor veli palatini muscle helps to coordinate the functions by opening and closing the Eustachian tube. This muscle is innervated by the

mandibular branch of the trigeminal nerve.<sup>15</sup>

According to Fysh, otitis media has four main elements to help one better understand its pathogenesis. One, otitis media is more commonly seen in young children. Two, the Eustachian tube is not fully developed in younger children and fluid is not able to flow freely from the middle ear to the nasopharynx due to misalignment. Three, otitis media is more commonly seen in the winter months; incidence of upper respiratory infections are typically higher at this time. Four, the fluid in the middle ear more commonly contains bacteria, rather than sterile effusion.<sup>9</sup>

Additional epidemiological factors that are thought to increase risk of otitis media in a patient are as follows: sibling with history of otitis media, bottle-fed infants, exposure to tobacco smoke, daycare attendees, prior antibiotic history, and male gender.<sup>2,3,16</sup> One author states that birth malposition and caesarian section children have a higher incidence of otitis media, due to the lack of cranial molding during the birth process, which "alters the proper juxtaposition of the cranial bones and potentially alters the pressure gradients within the ear mechanism."<sup>17</sup>

Signs and symptoms of otitis media include pain accompanied with tugging or pulling on the ears, fever, irritability, listlessness, and loss of hearing.<sup>9</sup>

#### *Alternative Treatments*

Antibiotic therapy, typically for 7-10 days is the most common treatment for otitis media by U.S. medical doctors; 98% of all patients follow this regime.<sup>2,5,18</sup> Antibiotics do not help in some situations though; viral infections and allergies do not respond to antibiotics and antibiotics have minimal effect on clearing the middle ear of excess fluid.<sup>9</sup>

In about 80% of children the condition resolves without antibiotic treatment in about three days. Complications are rare but include hearing loss, mastoiditis, meningitis, and recurrent attacks.<sup>19</sup> Some doctors are opting for a "Watch and See Prescription" or WASP approach to reduce the amount of antibiotics given to children afflicted with non-severe otitis media. This approach encourages parents to wait 48 hours before filling a prescription for antibiotics to see if the child gets better.<sup>20</sup>

Fluid that becomes uncontrollable in the middle ear can potentially rupture the tympanic membrane. Myringotomy with tympanostomy ventilating tube insertion will attempt to drain the excess fluid and reduce pressure. Tubes remain in place for up to six months and a reduction in symptomatology has been reported.<sup>9</sup> A naturopathic treatment for otalgia, a symptom in otitis media, suggests the use of Naturopathic Herbal Extract Ear Drops (NHED), which concluded in a study to be very beneficial.<sup>21</sup>

#### *Chiropractic Literature*

Several studies have been written on the positive effects of osteopathic manipulation for treatment of otitis media.<sup>3,22,23</sup> Manipulative treatment is gentle and is used to correct distortions or imbalances within the musculoskeletal system.<sup>3</sup>

A pilot study of eight children (all under the age of three years old) received weekly osteopathic manipulation for the treatment of recurrent acute otitis media.<sup>3</sup> Treatments were administered once weekly for a fifteen day period over the course of three weeks. No manipulations were performed after this fifteen day period, however, subjects were able to receive routine medical care on an as-needed basis. Gentle membranous procedures were given by the primary investigator and included myofascial and cranial release as well as manual treatment. One year following this treatment, phone interviews were conducted (by the primary investigator) in order to evaluate the rate of recurrence. The one year follow up revealed: five of eight children had no documented episodes of acute otitis media following the three week intervention period.

A multisite prospective randomized controlled trial to study the effects of osteopathic manipulation versus routine pediatric care in regards to recurrent acute otitis media was conducted.<sup>22</sup> Fifty seven patients were enrolled and divided into two separate groups; the intervention group received routine pediatric care plus osteopathic manipulative treatment and consisted of twenty-five subjects. The second group/control group received routine pediatric care alone and consisted of thirty-two children. Patients who were six months to six years old and who had experienced three episodes of acute otitis media within the previous six months or four episodes within the previous year were valid candidates. Treatment was gentle and was administered to areas of restriction. Techniques utilized included: myofascial release, balanced membranous tension, balanced ligamentous tension, facilitated positional release, and/or counterstrain treatments. High velocity, audible manipulations were not employed in this study. Conclusions of this study showed that the intervention group had fewer episodes of acute otitis media, fewer surgical procedures, and more mean surgery-free months.

The Galbreath technique is an osteopathic manipulative technique that has been shown to aid in the resolution of otitis media (through manipulation of the mandible) by increasing the blood flow to and through that region.<sup>23</sup> The primary drainage path for the middle ear and Eustachian tube is handled by the pterygoid plexus of veins and lymphatics; it is this specific area that is theorized to be targeted by this technique. Dr. Harrington in his article describes the proper protocol for performing this technique:

"The physician can perform this technique by either placing the child in the supine position (as originally described) or in the physician's or parent's lap. The physician then turns the child's head so that the affected ear faces away; with the operator's hand that is opposite of the affected ear (that is, if the child has otitis media on the right side, the operator uses the left hand), the operator contacts the child's mandible on the affected side and applies a downward and transverse mild force on the mandible that crosses the face. This is repeated in a slow rhythmic application of force (about 3 to 5 seconds per round) for 30 to 60 seconds. As stated, this technique can be taught to the patient's guardian and performed approximately three times daily."<sup>23</sup>

A case study of a 14-month-old girl diagnosed with acute

otitis media underwent Galbreath technique and had an immediate reduction in fever, erythema, and appeared to be more comfortable.<sup>23</sup> Additionally she completed a course of antibiotics to treat this episode of otitis media however, the patient received this manipulation when symptoms of otitis media began again and had not been placed on antibiotics since.

The literature on chiropractic management of a patient with otitis media shows positive, lasting results.<sup>1,8,9,17,18,24-33</sup> Following is a selected review of the literature concerning chiropractic intervention for otitis media.

An observer-blinded, randomized feasibility study including twenty patients aged six months to six years was conducted.<sup>1</sup> Participants received either a chiropractic spinal manipulation or a placebo/sham chiropractic spinal manipulation. Manual static and motion palpation was used to determine the areas to be treated for both groups. Regarding the active group, spinal manipulation was focused to the upper cervical area, however, did not exclude the rest of the spine. Low amplitude high velocity manual spinal manipulation was applied to specific affected spinal segments. Light touch of specific spinal segments was used for the placebo group. Objective measures used to evaluate the status of the middle ear included otoscopy and tympanometry. All participants were required to attend ten treatment appointments over a four week period; compliance was excellent. The results showed no serious side effects from either active or placebo manipulations.

The aim of a cohort, non-randomized retrospective study of forty-six children aged five years old or younger was to determine if patients improved under chiropractic care as well as to determine how many treatments were needed to reach improvement.<sup>18</sup> The subluxations of the forty-six children (aged five years and younger) were adjusted usually with an Activator, with particular attention paid to the cervical vertebrae and occiput. Applied Kinesiology and Sacro-Occipital blocking were also used to adjust the participants. The treatment regimen consisted of three treatments per week for one week, then two treatments a week for one week, then one treatment per week. Treatment was terminated when there was improvement. 93% of all episodes improved while under care and 75% improved in ten days or fewer. 43% had improvement with only one or two treatments. This is another study that serves to show how chiropractic care may decrease the symptoms of ear infections in young children.

In the study by Ressel and Rudy, 650 children under chiropractic care were studied. Otitis media was only one of the immune complaints that were examined.<sup>30</sup> The authors feel that there may be a factor in a child with otitis media that is not necessarily caused by an immature immune system which is a theory as to the onset and cause of otitis media. Van Breda substantiates this theory by showing that 80% under standard medical care experience ear infections versus only 31% of children experiencing otitis media under chiropractic care.<sup>30</sup>

In a case series of 332 children (aged 27 days to 5 years) with otitis media, chiropractic adjustive care using tympanography as an objectifying measure was used.<sup>17</sup> Static and motion palpation as well as examination of the cranium was performed in order to determine the presence or absence of

subluxation. Each child was given a series of chiropractic adjustments in accordance with the clinical findings as well as soft tissue effleurage involving the sternocleidomastoid muscles bilaterally. The results of this study indicate that there was a strong correlation between the resolution of otitis media and chiropractic adjustments.

Another case series involved five children with chronic recurrent otitis media who had been under the regular care of a pediatrician for this condition for a minimum of six months without resolution.<sup>9</sup> Each case received a spinal adjustment to the C2 segment as determined from a chiropractic examination; static and motion palpation were utilized to help find fixated segments. Each child's temperature was also recorded throughout the study and resolution of the condition was determined by otoscopic examination findings as well as reduction of fever. Every case responded favorably to chiropractic spinal adjustments with no complications noted; none of these cases required more than five treatments.

Toftness chiropractic technique was used on twenty-two children who had acute otitis media and who had not received any prophylaxis for it.<sup>27</sup> A Toftness adjustment consists of delivering a low force (2-32oz.) by a metered hand held pressure applicator at the desired segments. Both inner ear inflammation and bulging tympanic membranes as well as oral temperature improved after the Toftness adjustment was given.

A review of two case studies with children suffering from chronic otitis media also shows favorable results. The first case involved a fourteen-month old boy who had received 13 series of antibiotics (all progressively stronger) for the treatment of his otitis media.<sup>31</sup> Posture evaluation, gait, digital and motion palpation were all used to assess this patient's spine. The diagnosis was a C1 (Atlas) subluxation and care consisted of gentle manual thrusts on this vertebrae. By the sixth week of care the child was free from any ear infection for the first time in his life as determined by his pediatrician. The second case involved a six year old boy who had suffered from four to five sinus infections per year with at least two of these episodes leading to ear infections. Postural evaluation and palpation revealed the diagnosis of subluxations at C1, C2, T5-T7, L5 and sacrum. Segmental adjusting was preformed in the cervicals and mirror image adjusting (of postural imbalances) was utilized at the other segments. The mother reported increased improvements in her child's health within three weeks. One year from his first adjustment the child had not had a recurrence of any sinus infections or otitis media.

Another review of two cases also shows promising results from chiropractic care. The first case involved a four year old boy with otitis media undergoing two years of antibiotic therapy with negative results.<sup>29</sup> Subluxations of C1 and C2 were diagnosed from an x-ray exam and an surface electromyography (SEMG) study. These areas were monitored and adjusted when indicated using a toggle type thrust. Dramatic improvement was reported within two weeks time. The second case involved a six-year-old male who underwent three years of intermittent antibiotic therapy and was now being advised to have tubes inserted. Two sets of

tubes were inserted and the first set did not alleviate any complaints. The second set was inserted and more antibiotic therapy was instituted at that time in order to help eliminate symptoms. This second attempt was also unsuccessful. Palpation and instrumentation was utilized to determine the area of subluxation, which in this case was the upper cervical spine. Toggle protocol was used to adjust this child. The mother reported that by the fourth adjustment the child had not complained about his ears.

A case study of a five-year-old male with reoccurring otitis media was reviewed. The child's mother reported that he had suffered from numerous complaints such as fever, sinus and respiratory infections as well as otitis media since starting day care at the age of three months.<sup>28</sup> The child had received Amoxicillin and other antibiotics as well as drainage tubes. The mother reported that neither interventions had helped and that the tubes only lessened the pain but didn't prevent recurring infections.

Global spinal adjusting using CBP (Chiropractic Biophysics) technique was initiated including mirror image adjusting. At the child's second visit he had already reported that he felt better. Follow up adjustments were given three times a week for two weeks, then twice a week for two weeks, then once a week for six weeks and continued once every three weeks for six months. The child's otitis media with effusion was resolved in this case with chiropractic care.

A case study by Thomas describes an eleven-month-old male infant experiencing extreme irritability and chronic ear effusion with infection.<sup>25</sup> The infant's ear infection was reported to have begun within the first month following birth and continuing for twelve months. The mother had a forceps delivery accompanied with an epidural. Diversified chiropractic adjusting procedures were applied to the C1 vertebrae during most office visits. Other segments were also adjusted over the course of six months, however C1 required care on 80% of the visits made. The child had not experienced another ear infection after eight weeks of chiropractic care.

A recent case study of an 8 year old female with a three year history of otitis media as well as sinus infections, cephalgia and cervicgia also found improvement from chiropractic care - specifically CBP Technique.<sup>32</sup> The patient underwent two previous bilateral tympanectomy surgeries, several rounds of antibiotics, and sinus surgery before chiropractic care was sought.<sup>32</sup> Subjective and objective findings as well as all other complaints were absent, according to her pediatrician, one year after the start of chiropractic care.

Another case study involves a 3 year old girl who had hearing loss after three unsuccessful implantations of tympanostomy tubes.<sup>33</sup> High velocity, low amplitude adjustments were delivered to C1 using Diversified Technique. Additionally, cervical distraction exercises were recommended as part of the patient's care plan. The child's mother reported that she had less ear pain, better speech and was less irritable after the initiation of chiropractic care. The patient also reported that she experienced an improvement in hearing and an audiology evaluation showed improved hearing in both ears.

Lastly, a three and a half year old boy underwent chiropractic

care in order to help resolve a ten month history of otitis media with effusion.<sup>8</sup> There was continuous, odiferous discharge emanating from both of his ears and the patient had been diagnosed with a hearing deficit. He had subluxations present in the cervical and thoracic regions and was treated four times. After his first adjustment, discharge from the ears disappeared immediately. Three months after the cessation of his chiropractic care, a hearing test showed improvement in his hearing.

## Conclusion

The purpose of this case study was to present a patient with otitis media and describe the management with chiropractic care as the method of treatment. Many otitis media cases that fail to resolve medically are brought to a chiropractor.<sup>32</sup> A review of the literature showed favorable and lasting results for patients utilizing chiropractic care to treat otitis media. Unlike the typical allopathic method of attempting to kill the bacteria or virus, chiropractic seeks to restore normal function of the nervous system, ears and deep cervical lymphatics.<sup>28</sup>

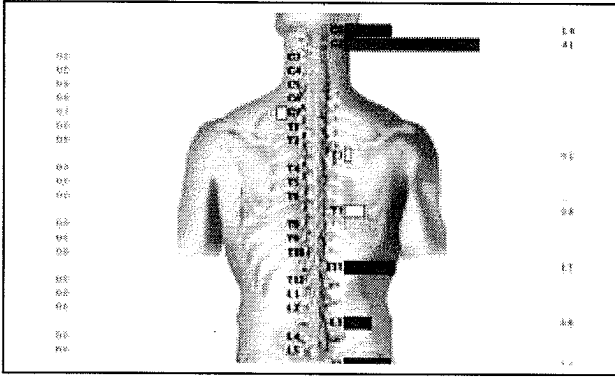
The patient in this case was evaluated and accepted for chiropractic care and was carefully assessed for vertebral subluxations and then adjusted accordingly. The patient has had no recurrence of ear infections since the initial adjustment. It is concluded that chiropractic care was successful in treating this patient for otitis media. Further research concerning the efficacy of chiropractic care and otitis media is recommended.

## References

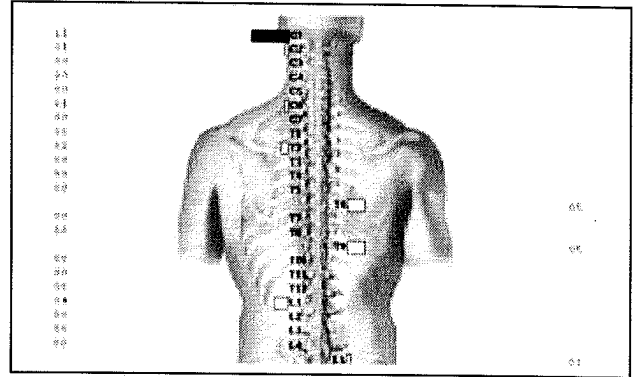
1. Sawyer CE, Evans RL, Voline PD, Branson R, Spicer A. A feasibility study of chiropractic spinal manipulation versus sham spinal manipulation for chronic otitis media with effusion in children. *J Manipulative Physiol Ther.* 1999 Jun;22(5):292-8.
2. American Academy of Pediatrics Subcommittee on Management of Acute Otitis Media. Diagnosis and management of acute otitis media. *Pediatrics* 2004;113-1451-1465.
3. Degenhardt BF, Kuchera ML. Osteopathic evaluation and manipulative treatment in reducing the morbidity of otitis media: a pilot study. *J Am Osteopath Assoc.* 2006;106:327-334.
4. Bondy J, Berman S, Glazner J, Lezotte D. Direct expenditures related to otitis media diagnoses: extrapolations from a pediatric Medicaid cohort. *Pediatrics.* 2000;105:E72. Available at: <http://pediatrics.aappublications.org/cgi/content/full/105/6/e72>
5. Corbeel L. What is new in otitis media?. *Eur J Pediatr.* 2007;166:511-519.
6. Eser OK, Ipci K, Alp S, Akyol U, Unal OF, Hascelik G, Sennaroglu L, Gur D. Efficacy of nasopharyngeal culture in identification of pathogens in middle ear fluid in chronic otitis media with effusion. *Indian J Med Microbiol* 2009;27:237-41
7. Stenstrom R, Pless B, Bernard P. Hearing thresholds and tympanic membrane sequale in children managed medically or surgically for otitis media with effusion. *Arch Pediatr Adolesc Med* 2005;159:1151-1156.

8. Saunders L. Chiropractic treatment of otitis media with effusion: a case report and literature review of the epidemiological risk factors that predispose towards the condition and that influence the outcome of chiropractic treatment. *Clin Chiropr*. 2004;7:168-173.
9. Fysh PN. Chronic recurrent otitis media: case series of five patients with recommendations for case management. *J Clin Chiropr Pediatr*. 1996;1(2):66-78
10. American Academy of Pediatrics Subcommittee on Management of Acute Otitis Media. Management of acute otitis media by primary care physicians: Trends since the release of the 2004 American Academy of Pediatrics/American Academy of Family Physicians clinical practice guideline. *Pediatrics* 2007;120:281-287.
11. Keyhani S, Kleinman L, Rothschild M, Bernstein J, Anderson R, Chassin M. Overuse of tympanostomy tubes in New York metropolitan area: evidence from five hospital cohort. *BMJ* 2008;337a1607.
12. Kleinman LC, Kosecoff J, Dubois RW, Brooks RH. The medical appropriateness of tympanostomy tubes proposed for children younger than 16 years in the United States. *JAMA* 1994;271:1250-5.
13. Uematsu, E, et al. Quantification of thermal asymmetry, part 1: normal values and reproducibility. *J Neurosurg* 1988; 69: 552-555.
14. Phillips CJ. Craniosacral Therapy. In: Anrig C, Plaugher G, editors. *Pediatric Chiropractic*. Lippincott Williams & Wilkins; 1998. p. 424-6.
15. Barsoumian R, Kuehn D, Moon J, Canady J. An anatomic study of the tensor veli palatini and dilatator tubae muscles in relation to Eustachian tube and velar function. *Cleft Palate-Craniofacial Journal*. March 1998, Vol. 35 No. 2.
16. Rovers M. The burden of otitis media. *Vaccine* 2008, G2-G4.
17. Fallon JM. The role of the chiropractic adjustment in the care and treatment of 332 children with otitis media. *J Clin Chiropr Pediatr*. 1997;2(2):167-183.
18. Froehle RM. Ear infection: a retrospective study examining improvement from chiropractic care and analyzing for influencing factors. *J Manipulative Physiol Ther*. 1996 Mar/Apr;19(3):169-177.
19. O'Neill P. Acute otitis media. *BMJ* 1999 Sep 25;319:833-5.
20. Spiro DM, Tay K, Arnold DH, Dziura JD, Baker MD, Shapiro ED. Wait-and-see prescription for the treatment of acute otitis media. *JAMA*. 2006 Sep 13;296(10):1235-1241.
21. Sarrell EM, Cohen HA, Kahan E. Naturopathic treatment for ear pain in children. *Pediatrics*. 2003 May;111(5):574-9.
22. Mills MV, Henley CE, Barnes LL, Carreiro JE, Degenhardt BF. The use of osteopathic manipulative treatment as adjuvant therapy in children with recurrent acute otitis media. *Arch Pediatr Adolesc Med*. 2003 Sep;157:861-6.
23. Pratt-Harrington D. Galbreath technique: a manipulative treatment for otitis media revisited. *J Am Osteopath Assoc*. 2000 Oct;100(10):635-9.
24. Vallone S, Fallon J.M. Treatment protocols for the chiropractic care of common pediatric conditions: otitis media and asthma. *Journal of Clinical Chiropractic Pediatrics*. 1997;2(1):113-115.
25. Thomas D. Irritable child with chronic ear effusion/infections responds to chiropractic care. *Chiropractic Pediatrics*. 1997 Dec;2(2):13-14.
26. Lamm L, Ginter L. Otitis media: a conservative chiropractic management protocol. *Top Clin Chiro* 1998;5(1):18-28.
27. Zhang J.Q, Snyder B.J. Effect of Toftness chiropractic adjustments for children with acute otitis media. *J Vertebral Subluxation Res*. 2004 March;29:1-4.
28. Peet J. Case study: chiropractic results with a child with recurring otitis media accompanied by effusion. *Chiropractic Pediatrics*. 1996 April;2(2):8-10.
29. Webster L. A review of two typical chiropractic cases involving otitis media. *Chiropr Pediatr*. 1996 Apr;2(2):14-15.
30. Ressel O, Rudy R. Vertebral subluxation correlated with somatic visceral and immune complaints: an analysis of 650 children under chiropractic care. *J Vertebral Subluxation Res*. 2004 ;Oct(18):Online access only 23 p.
31. Heagy D. The effect of the correction of the vertebral subluxation on chronic otitis media in children. *Chiropractic Pediatrics*. 1996 April;2(2):6-7.
32. Fedorchuk C, Cohen A. Resolution of chronic otitis media, neck pain, headaches & sinus infection in a child following an increase in cervical curvature & reduction of vertebral subluxation. *J. Pediatric, Maternal & Family Health*. 2009 June Issue 2:1-8.
33. Brown C. Improved hearing and resolution of otitis media with effusion following chiropractic care to reduce vertebral subluxation. *J. Pediatric, Maternal & Family Health*. 2009 March Issue1:1-7.

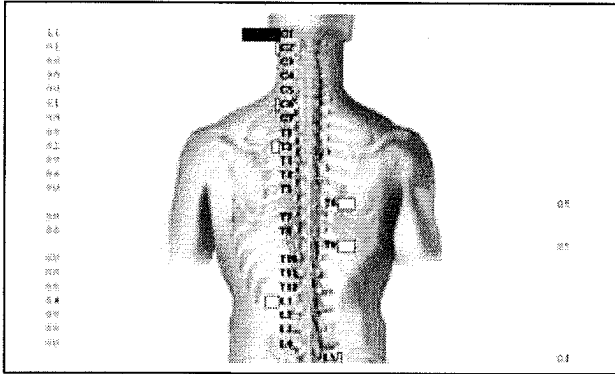
**Figure 1 – Initial Thermal Scan**



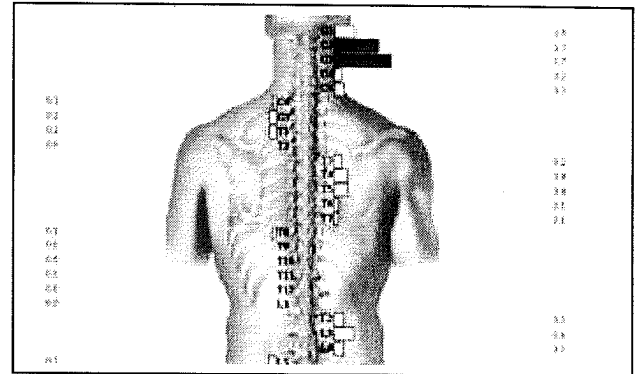
**Figure 3 – Thermal Scan – 2 Months Later**



**Figure 2 – Thermal Scan – 1 Month Later**



**Figure 4 – Thermal Scan – 1 Year Later**



Thermal scans taken over a one year period demonstrate a persistent upper cervical pattern of dysfunction consistent with physical examination findings of vertebral subluxation in this area.